

# Pineal region tumors: A diverse pathology in the seat of the soul

Rajiv Jha<sup>1</sup>, Jagannath Tiwari<sup>2</sup>

<sup>1</sup>National Neurosurgical Referral Center, NAMS Bir Hospital, Kathmandu, Nepal.

<sup>2</sup>Bharatpur Hospital, Bharatpur, Chitwan, Nepal

**Correspondence:** Dr. Rajiv Jha, Professor of Neurosurgery, National Neurosurgical Referral Center, NAMS Bir Hospital, Kathmandu, Nepal.

**Email:** medrajiv18@hotmail.com

## Abstract

**Introduction:** Pineal region tumors include a variety of neoplasms of different histological origin arising from the pineal gland itself and from structures of the parapineal area. It is a rare tumor which accounts for 0.4-1% of all intracranial tumors. The objective of this study was to describe the epidemiology, clinical presentation and histopathology of pineal region tumors at National Neurosurgical Referral Center, Nepal.

**Methods:** This was a descriptive study of all cases of pineal region tumors which were operated between January 2013 and December 2019 at National Neurosurgical Referral Center, National Academy of Medical Sciences, Bir Hospital.

**Results:** A total of 14 cases were operated during the study period. The mean age was 12 years (4-50 years) with male preponderance (64%). Most of these patients had clinical features of raised intracranial pressure due to obstructive hydrocephalus followed by oculomotor sign in the form of Perinaud syndrome and endocrine dysfunction. Most common histopathology was Pineoblastoma in our study (4 out of 14).

**Conclusion:** Pineal region tumors are most commonly seen in adolescent age group. Most common symptoms were features of raised intra cranial pressure due to hydrocephalus followed by Perinaud syndrome. Pineal region tumors consist of diverse histopathological variants.

**Keywords:** Germ cell tumor; Nongerminomatous tumors; Pineal gland; Pineoblastoma; Pineocytoma; Tumor of pineal region.



DOI: <https://doi.org/10.3126/jssn.v23i1.33524>

## Introduction

Tumors of the pineal region represent a diverse collection of tumors which may involve not only the pineal gland itself but also posterior portion of the third ventricle, tectum and aqueduct of the midbrain. The histological heterogeneity of tumors is associated with vastly different prognosis and reflects the variety of cell types which present in this area. According to the World Health Organization (WHO) tumor classification, pineal region tumors include four principal groups<sup>1-4</sup>

1. Germ cell tumors
2. Pineal parenchymal tumors
3. Gliomas
4. Tumours of other histology (meningiomas, PNET, neurocytomas, haemangioblastomas, cavernomas and metastasis)

Pineal region tumors account for 0.4-1% of all primary brain tumors and approximately two third of these tumors are malignant.<sup>1,3,5,6</sup>

The clinical course of pineal region tumors depends on tumor histology. The rate of tumor growth determines the rapidity of symptom onset. In cases of malignant tumors, rapid progression of the disease occurs within several months or even weeks. In contrast, benign tumors such as tectal gliomas many not change their size over many years. Pineal tumors cause neurogenic dysfunction by direct invasion, compression or obstruction of cerebrospinal fluid flow. The most common presentation is headache, nausea, vomiting, dizziness due to compression of the cerebral aqueduct, resulting in obstructive hydrocephalus. Perinaud syndrome which includes vertical gaze palsy is the most common of the oculomotor symptoms that results

from pressure on the pretectal region. Tumor invasion of the midbrain may cause various oculomotor symptoms due to involvement of different ocular motor nuclei and pathways. Magnetic resonance imaging (MRI) is the most useful initial study to determine the relationship of pineal tumors to adjacent structures. The treatment options for the different pineal region tumors vary according to their histological nature. Histopathology of the pineal region tumors is also varied.

Since pineal region tumors are rare and have diverse histology as well as clinical presentation, we conducted this study with an objective to describe the epidemiology, clinical presentation and histopathology of pineal region tumors at National Neurosurgical Referral Center, Nepal.

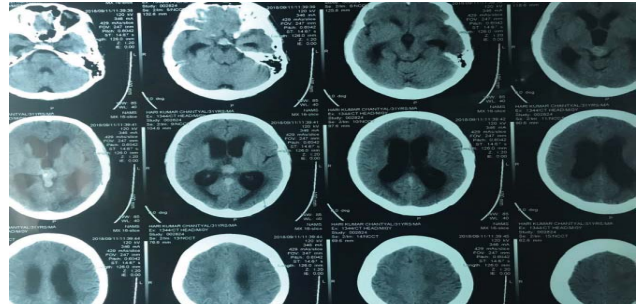
## Methods

This was a descriptive study of 14 cases of pineal region tumors. This study was carried out at National Neurosurgical Referral Center (NNRC), National Academy of Medical Sciences (NAMS) Bir hospital. Institutional review board (IRB) approval was taken from the hospital for the study. Consent was taken from the patients if they were able to communicate and from the next of kin if they were not able to give consent. All tumors arising from pineal region were included in this study except the patient who had positive cerebrospinal fluid tumor markers. The duration of the study was from January 2013 to December 2019. Age, sex, clinical presentations and neurological manifestations were noted. Outcome was measured on the basis of extent of tumor excision, histopathological types and Glasgow Outcome Scale (GOS) at three months (Grade 1- Death, Grade 2- Persistent vegetative state: Minimal responsiveness, Grade 3- Severe disability: Conscious but disabled; dependent on others for daily support, Grade 4- Moderate disability: Disabled but independent; can work in sheltered setting, Grade 5- Good recovery: Resumption of normal life despite minor deficits).

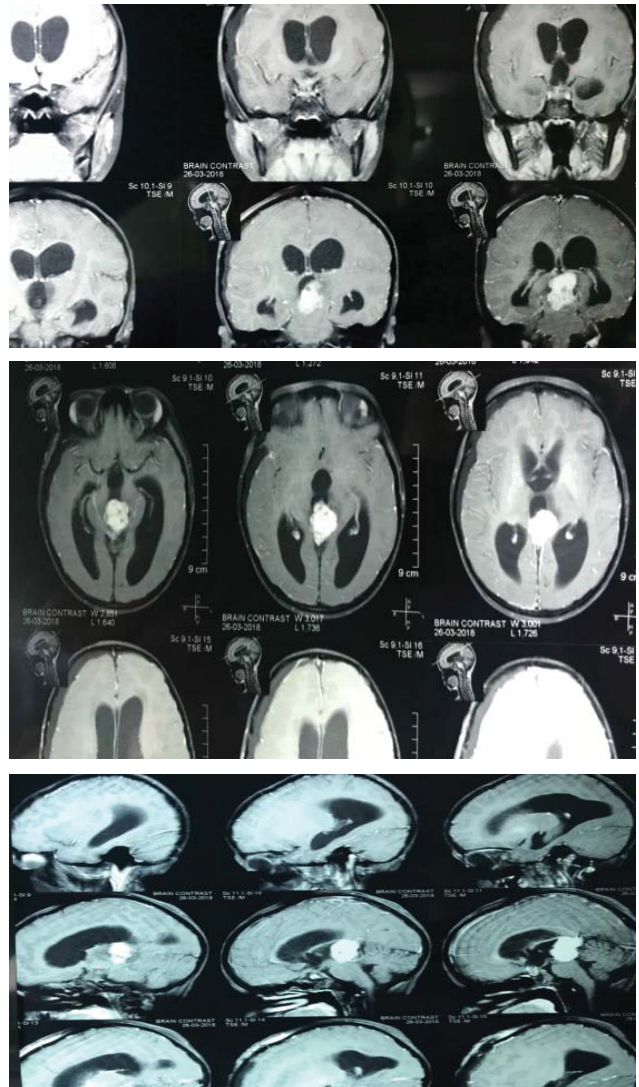
## Results

Fourteen cases were operated during the study period. The mean age was 12 years (range 4-50 years). The tumors were most common in the paediatric population (6) and young adults (4). Male had preponderance (64%) versus female (36%). Most of these patients had clinical features of raised intracranial pressure due to obstructive hydrocephalus in 13 cases (93%) followed by oculomotor sign in the form of Perinaud syndrome in five patients (36%) and endocrine dysfunction in four patients (29%). Hydrocephalus was typically triventricular.

All these patients were investigated with both contrast CT scan and MRI of the brain. **Figure 1** and **Figure 2** show typical pictures of a pineal region tumor in CT and MRI respectively. One patient also needed CT cerebral angiography to evaluate the relationship of tumor with surrounding blood vessels.

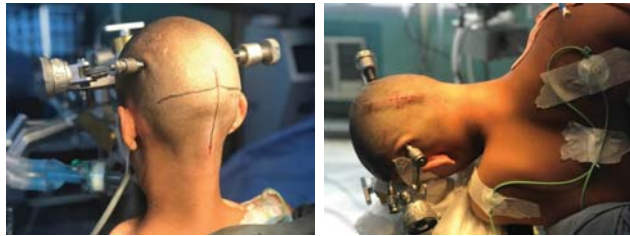

**Figure 1. CT Scan shows hyperdense lesion in the posterior part of third ventricle associated with hydrocephalus.**

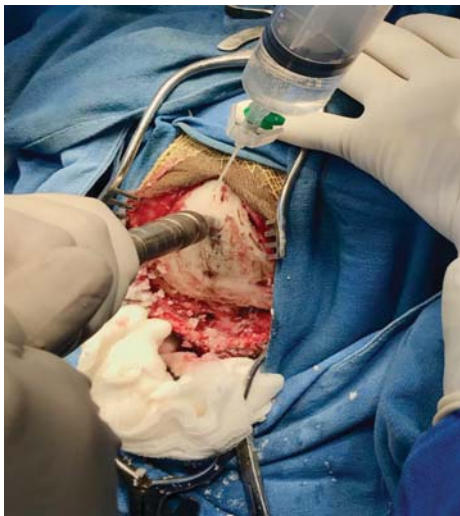



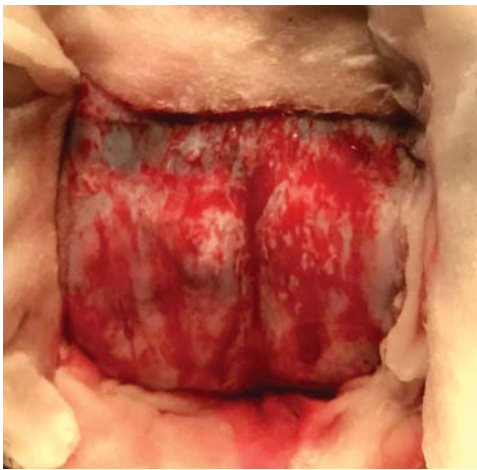
**Figure 2.** MRI Brain shows altered signal intensity in posterior part of third ventricle which is heterogeneous iso signal intensity in T1WI, high signal intensity in T2WI. On post contrast study, the lesion shows mild enhancement.



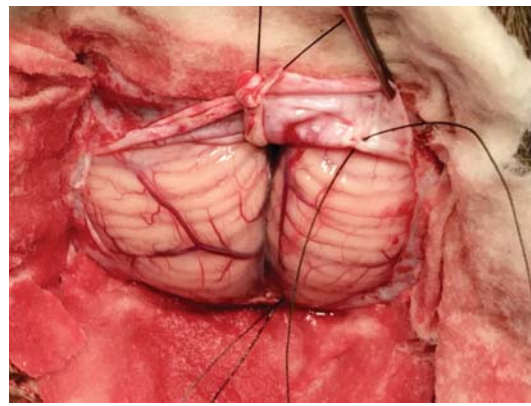
**Figure 3.** Patient position: Semi sitting and Three Quarter Prone position



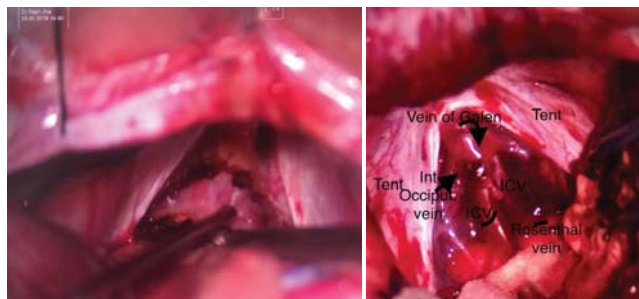
**Figure 4.** craniotomy by doing 4 point burr holes, at occipital protubance, at about 1 cm above foramen magnum, and at bilateral lateral side along transverse and sigmoid sinus junction.



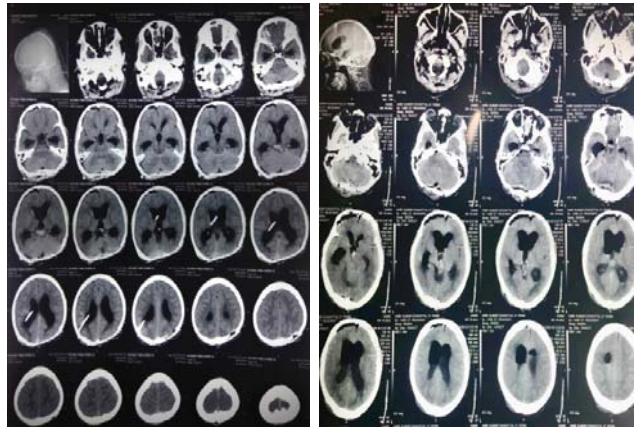
**Figure 5:** Dural exposure: must widely expose transverse sinus superiorly



**Figure 6:** Opening of Dura: dura should be opened in curve shape, few stitches must be applied along the edges of opened dural leaf followed by in the tent.



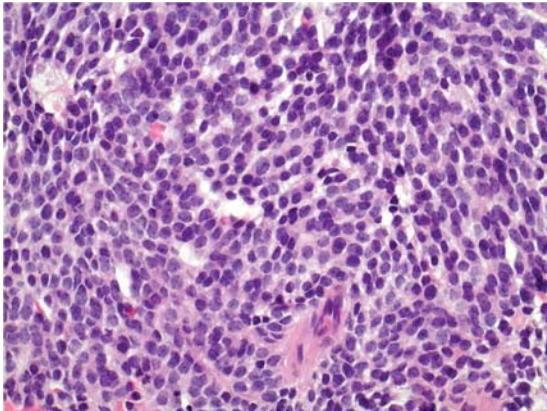
**Figure 7.** Intra operative picture showing pineal tumor and other structures.



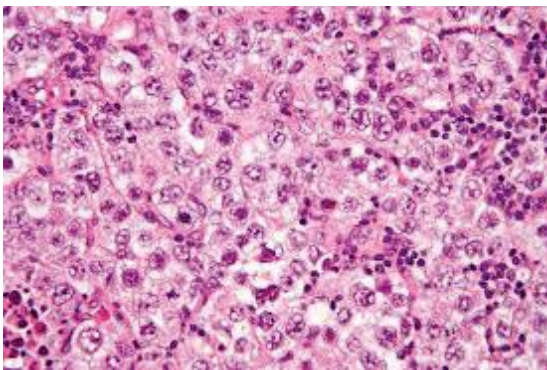
**Figure 8.** Post-operative CT Scan showing total excision of the tumor with pneumocephalus and pneumoventricle.

**Table 1. Histopathology**

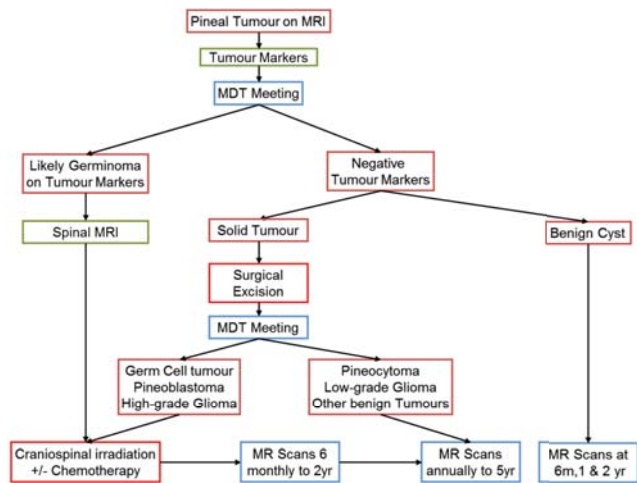
Type	Grade	Number
Germinoma		2
Pilocytic Astrocytoma	I	2
Diffuse Astrocytoma	II	2
Pineoblastoma	IV	4
Intermediate Differentiation	II,III	1
Teratoma	II	1
Meningioma	I	2



**Figure 9. Histopathology of pineoblastoma shows sheets of densely packed cells with high grade (anaplastic / undifferentiated) features with minimal cytoplasm and large hyperchromatic nuclei**



**Figure 10. Histopathology of germ cell tumor shows Large, epithelioid cells with abundant cytoplasm, large, round nuclei and irregular and pleomorphic nuclei**



**Figure 11. Flowchart management of patients with pineal region tumor.**

In suspected five cases of germinomatous tumor, tumor markers were examined in serum and cerebrospinal fluid (CSF) especially for alpha Fetoprotein (AFP), Beta Human chorionic gonadotropin (B-HCG), alkaline phosphatase (Apo4) and carcinoembryonic antigen. AFP and B-HCG were present in CSF and in serum in one of the patients, while only AFP was positive in serum of another patient.

Out of the 14 cases, 12 were operated in semi sitting position, while two cases were operated in three quarter prone position (Figure 3). All the cases were operated by using infratentorial supracerebellar approach (Figure 4-7). Total excision of the tumor was achieved in 12(86%) of the cases. All patients had postoperative CT scan of the brain to evaluate the extent of surgical resection and presence of any other complications like pneumocephalus (Figure 8). Postoperative period was uneventful for all cases and there was no mortality. All patients had favorable Glasgow Outcome Scale.

Most common histopathology was Pineoblastoma in our study. Other histopathologies were germinoma, pilocytic astrocytoma, diffuse astrocytoma, pineoblastoma, teratoma and meningioma (Figure 9,10) (Table 1).

### Discussion

Pineal region tumors account for 0.4-1% of all primary brain tumors and approximately two third of these tumors are malignant.<sup>1,3,5,6</sup> They represent 3% of all pediatric intracranial neoplasms.<sup>7</sup> Pineal region masses include those that originate from the pineal gland, as well as those that arise from adjacent structures. Masses of the pineal region range from simple benign cysts to high-grade neoplasms.



The pineal gland ranges in size from 10-14 mm and is located within the midline above the tentorium and superior colliculi and below the splenium of the corpus callosum and vein of Galen. It develops as a diverticulum in the diencephalon roof of the third ventricle during the second month of gestation. The gland itself is attached to the posterior aspect of the third ventricle by the pineal stalk. The mature gland secretes melatonin, an endocrine hormone involved in multiple pathways, but most commonly known for its association with circadian rhythms. The pineal gland is composed of 95% pineocytes (specialized neurons related to retinal rods and cones) and 5% astrocytes. Unlike most intracranial structures, the gland is outside of the blood-brain barrier.<sup>8</sup>

Small pineal masses may be asymptomatic, but as lesions increase in size, they compress adjacent structures and may become symptomatic. Poppen and Marino initially suggested three clinical phases to pineal region masses: 1) headaches with nausea and vomiting; 2) blurred vision, diplopia, changes in mental states, drowsiness, papillary changes, ataxia or dizziness, and paralysis of the extra-ocular muscles; 3) papilledema, weakness, and spasticity.<sup>9</sup> Two common syndromes associated with pineal region masses include the Sylvian aqueduct syndrome and Parinaud syndrome. These syndromes are similar and result from compression of the mesencephalon. Typical clinical findings include paralysis of upward gaze, abnormalities of the pupil, and nystagmus retractorius. One dreaded complication of a pineal region mass is pineal apoplexy, which are sequelae of hemorrhage into a pineal cyst or tumor with sudden decrease in consciousness and headache.<sup>10</sup> Magnetic resonance imaging (MRI) is the most useful initial study to determine the relationship of pineal tumors to adjacent structures.

The treatment options for the different pineal region tumors vary according to their histological nature. However, with the exception of germinomas which can be nowadays cured by low-dose radiotherapy and chemotherapy and only require a biopsy for diagnosis, surgery still plays a central role in the management of most of the other pineal region tumors, followed or not by adjuvant radiotherapy, chemotherapy or a combination of both. The first successful removal of a pineal tumor was reported in 1913 by Oppenheim and Krause. Krause was the first to describe and successfully use the infratentorial supracerebellar approach in three cases in 1926.<sup>11</sup> In the micro-surgical era Stein further developed and popularized this approach during the 1970s.<sup>12</sup> Finally the right suboccipital approach was described by Poppen and further modified by Jamieson in 1971.<sup>13</sup> The infratentorial supracerebellar and the

occipital transtentorial approaches are nowadays accepted as the main standard accesses to the pineal region.

Germ cell tumors are the most common, particularly germinoma, followed by pineal cell tumors, to include pineocytomas and pineoblastomas.<sup>14</sup> Germinoma and astrocytoma were the commonest histopathological findings in our study as well.

Details and treatment options for different pineal region tumors are as follows:

**Germinomas:** Germinomas are the most common tumor in this region and are highly radiosensitive with expectations of 80 – 90% long term survival when adequate (> 55 Gy) radiation doses are given to the tumor and surrounding ventricles (ventricular field irradiation).<sup>15</sup> Value of chemotherapy for germinomas is yet to be conclusively proven. Pediatric Oncology Group (POG) study demonstrated extensive spinal relapses using exclusive chemotherapy protocols. Therefore chemotherapy should only be recommended as first treatment in very young children.<sup>16</sup>

Combination chemoradiotherapy for germinomas is interesting and showed encouraging results, especially in reducing the brain's overall radiation exposure.<sup>17</sup> Chemoradiation protocol is an alternative to radiation therapy alone and it is probably best advocated for higher grade germinomas (germinomas with high  $\beta$ -HCG).

**Non Germinomatous Germ Cell Tumors:** Non-germinomatous malignant germ cell tumors (NGGCT) including endodermal sinus tumors, choriocarcinomas and embryonal carcinomas carry a poor prognosis. Most are diagnosed on the basis of elevated  $\beta$ -HCG or  $\alpha$ -fetoprotein levels or on histological diagnosis from tissue biopsy. In NGGCT study, comparing upfront chemotherapy prior to radiotherapy with radiotherapy alone, resulted in 5-year survival rate of 65% vs. 30% respectively.<sup>18</sup> From this study, they concluded that these tumors are radiosensitive but still require adjuvant chemotherapy for optimal long-term survival.

**Intermediate Grade Pineal Parenchymal Tumors and Pineoblastomas :** Intermediate grade pineal parenchymal tumors and pineoblastomas are highly aggressive tumors. Various clinical trials including pineal and non-pineal PNET have universally advocated gross total resection and adjuvant radiation and/or chemotherapy for these tumors.<sup>19,20</sup> Improvement in chemotherapy regimens may reduce the effective radiation dose in children older than four years and therefore avoiding the radiation complications.

**Teratomas:** Combination of radio and chemotherapy is the treatment of choice for mixed (mature and immature teratomas) and immature or malignant teratomas. Minimally invasive endoscopic biopsy is the preferred strategy to obtain the initial tumor tissues for actual diagnosis. Debulking surgery is reserved for large tumor to make it susceptible for adjuvant therapy and to reduce cranial radiation dose and therefore cranial toxicity. On the contrary, for patients with mature teratomas, the treatment of choice is surgical resection.<sup>21</sup>

**Gliomas:** Astrocytomas arising in pineal gland are often cystic and complete surgical resection is achievable resulting in probable cure.<sup>22</sup> A large tumor, thought to be a glioma, is normally treated first with biopsy procedure of either stereotaxy or endoscopy to confirm the histological diagnosis. Once confirmed, the high grade gliomas (except butterfly gliomas, which are treated conservatively) are normally treated with radical surgery to debulk the tumor followed by radiation therapy; radiosurgery, stereotactic radiotherapy or intraoperative radiotherapy. The role of adjuvant radiation therapy for benign gliomas is debated.

**Benign Pineal Region Tumors:** These include Meningiomas, Epidermoids, Pineocytomas, Pineal and Arachnoid Cysts. Benign pathology is associated with excellent prognosis with surgery. Aggressive open surgical treatment with the goal of gross total resection invariably results in long term remission and potential cure. Minimally invasive endoscopic surgery is sometimes the treatment of choice for benign cystic lesions such as epidermoid and symptomatic pineal cysts. Radiation therapy may have a role for inoperable benign tumors such as meningiomas or pineocytomas. This type of therapy is normally opted for elderly or patients with multiple medical problems

## Conclusion

Pineal region tumors are most commonly seen in adolescent age group. Most common symptoms are features of raised intra cranial pressure due to hydrocephalus followed by Perinaud syndrome. Pineal region tumors consist of diverse histopathological variants.

## Acknowledgement

The author would like to thank the patients and their relatives for providing consent to publish this article. The author would also like to thank Dr. Prabhat Kaushal Jha, 1<sup>st</sup> year resident at department of neurosurgery, NAMS Bir Hospital for his technical help during formatting this article.

**Competing interest:** none

## References

1. Jennings MT, Gelman R, Hochberg F. Intracranial germ-cell tumors: natural history and pathogenesis. *J Neurosurg.*1985;63(2):155-67.
2. Kleihues P, Louis DN, Scheithauer BW, et al. The WHO classification of tumors of the nervous system. *J Neuropathol Exp Neurol.*2002 Mar;61(3):215-29.
3. Schild SE, Scheithauer BW, Schomberg PJ, Hook CC, Kelly PJ, Frick L et al. Pineal parenchymal tumors. Clinical, pathologic, and therapeutic aspects. *Cancer.*1993 Aug 1;72(3):870-80.
4. Zulch KJ, Brain tumors: their histology and their pathology, ed 2. New York: Springer-Verlag, 1965, 326
5. Regis J, Bouillot P, Rouby-Volot F, Figarella-Branger D, Dufour H, Peragut JC. Pineal region tumors and the role of stereotactic biopsy: review of the mortality, morbidity, and diagnostic rates in 370 cases. *Neurosurgery.* 1996 Nov;39(5):907-14.
6. Kirkpatrick P. Neurosurgical management of aneurysmal subarachnoid haemorrhage. *J Neurol Neurosurg Psychiatry.* 2000 Apr;68(4):538E.
7. Villano JL, Propp JM, Porter KR, Stewart AK, Valyi-Nagy T, Li X et al. Malignant pineal germ-cell tumors: an analysis of cases from three tumor registries. *Neuro Oncol.* 2008 Apr;10(2):121-30.
8. Krause F: Operative Freilegung der Vierhügel, nebst Beobachtungen beim Hirndruck und Dekompression. *Zentralbl Chir.* 1926;53:2812-9.
9. Stein BM. The infratentorial supracerebellar approach to pineal lesions. *J Neurosurg.* 1971 Aug;35(2):197-202.
10. Jamieson KG: Excision of pineal tumors. *J Neurosurg.* 1971 Nov;35(5):550-3.
11. Mufti ST, Jamal A. Primary intracranial germ cell tumors. *Asian J Neurosurg.* 2012 Oct;7(4):197-202.
12. Smith AB, Rushing EJ, Smirniotopoulos JG. From the archives of the AFIP: lesions of the pineal region: radiologic-pathologic correlation. *Radiographics.* 2010 Nov;30(7):2001-20.
13. Poppen JL, Marino R Jr. Pinealomas and tumors of the posterior portion of the third ventricle. *J Neurosurg.* 1968 Apr;28(4):357-64.
14. Carr C, O'Neill BE, Hochhalter CB, Strong MJ, Ware ML. Biomarkers of Pineal Region Tumors: A Review. *Ochsner J.* Spring 2019;19(1):26-31.

15. Tien RD, Barkovich AJ, Edwards MS. MR Imaging of pineal tumors. *AJR Am J Roentgenol.* 1990 Jul;155(1):143-51.
16. Allen JC, DaRosso RC, Donahue B, Nirenberg A. A phase II trial of preirradiation carboplatin in newly diagnosed germinoma of the central nervous system. *Cancer.* 1994 Aug 1;74(3):940-4.
17. Kretschmar C, Kleinberg L, Greenberg M, Burger P, Holmes E, Wharam M. Pre-radiation chemotherapy with response-based radiation therapy in children with central nervous system germ cell tumors: a report from the Children's Oncology Group. *Pediatr Blood Cancer.* 2007 Mar;48(3):285-91.
18. Choi JU, Kim DS, Chung SS, Kim TS. Treatment of germ cell tumors in the pineal region. *Childs Nerv Syst.* Jan-Feb 1998;14(1-2):41-8.
19. Gururangan S, McLaughlin C, Quinn J, Rich J, Reardon D, Halperin EC et al. High-dose chemotherapy with autologous stem-cell rescue in children and adults with newly diagnosed pineoblastomas. *J Clin Oncol.* 2003 Jun 1;21(11):2187-91.
20. Gilheeneey SW, Saad A, Chi S, Turner C, Ullrich NJ, Goumnerova L et al. Outcome of pediatric pineoblastoma after surgery, radiation and chemotherapy. *J Neurooncol.* 2008 Aug;89(1):89-95.
21. Selçuki M, Attar A, Yüceer N, Tuna H, Cakiroğlu E. Mature teratoma of the lateral ventricle: report of two cases. *Acta Neurochir (Wien).* 1998;140(2):171-4.
22. Stein BM, Bruce JN. Surgical management of pineal region tumors (honored guest lecture). *Clin Neurosurg.* 1992;39:509-32.